


XXIII° Ciclo del Dottorato
“La patologia vascolare del distretto testa-collo”

**Non-microvascular alternatives to free radial forearm flap in
high risk patients with oral cavity and oropharyngeal defects.**



Alberto Deganello, MD
Otolaryngologist
Head and Neck Surgeon

Coordinatore

Prof. Ugo Menchini

Tutor

Prof. Oreste Gallo, MD

Desidero dedicare questa Tesi a due cari amici, due angeli custodi che mi sorridono dal Paradiso e che mi spronano a far bene il mio mestiere, Mauro Lentola (25/10/1968 - 29/03/2001) e Roberto Frizzarin (18/06/1972 - 08/07/2007) .



Mauro, sei mancato nel 2001 dopo un lunghissimo calvario. Ricordo la tua tenacia, la voglia di guarire di vivere di suonare, il bisogno di realizzare i tuoi sogni. Ricordo che papà Giulio era sempre presente, forte come una quercia, e poi tutti i tuoi amici e l'amore con cui ti hanno sostenuto giorno per giorno.



Roberto, te ne sei andato davanti ai miei occhi in un giorno d'estate del 2007. Il tuo sorriso, la tua prestanza fisica contrastavano con l'immagine di te nel letto d'ospedale. Siamo cresciuti assieme, quanti bei ricordi! Dopo la morte di mamma Annamaria sei dovuto diventare adulto improvvisamente e subito sei stato il fratello maggiore non solo per Gabriella e Walter ma per tutta Arre. Sempre allegro, ottimista, vulcanico, eri contagioso nella simpatia, brillante nell'intelletto e grande nel cuore. Non abbiamo neanche avuto il tempo per realizzare cosa stesse succedendo

che te ne sei andato. Non passa giorno che non pensi a te.

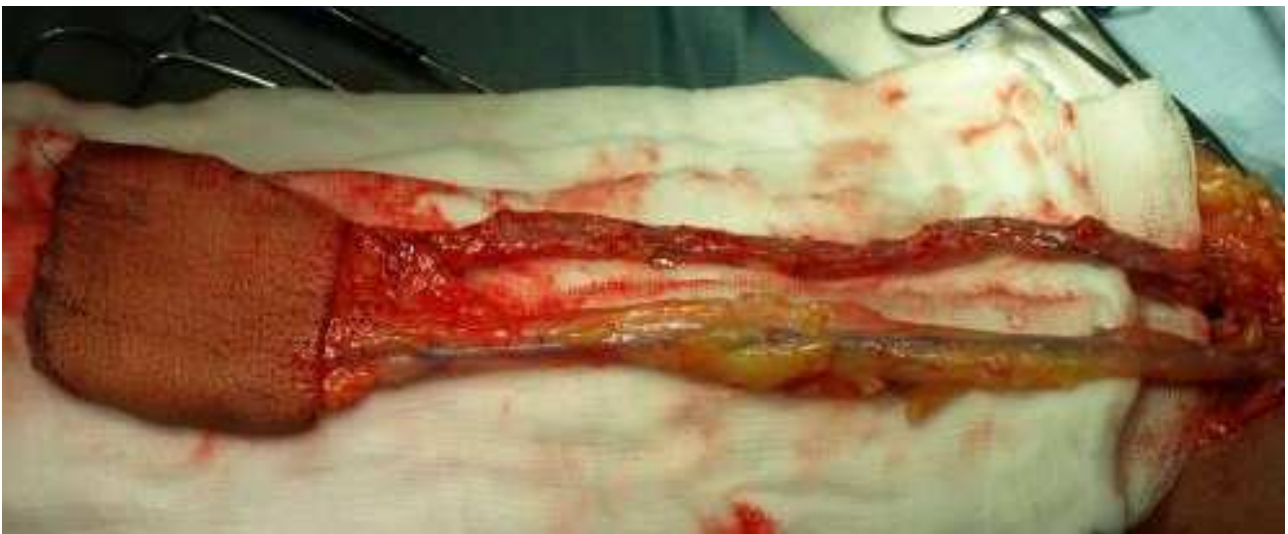INDEX

- INTRODUCTION page 4
- MATERIALS AND METHODS page 6
- RESULTS page 9
- DISCUSSION page 12
- CONCLUSION page 21
- ACKNOWLEDGMENTS page 21
- REFERENCES page 22

INTRODUCTION

The application of microvascular free flaps is the most widespread method currently employed for the reconstruction of extensive defects after resection of head and neck cancer because of their versatility and reliability. The success rate of free tissue transfers has risen to greater than 95%, and free radial forearm flap (FRFF) can be considered the procedural mainstay for soft tissue reconstruction of oral cavity and oropharyngeal defects¹.

Figure 1. *Free radial forearm flap*

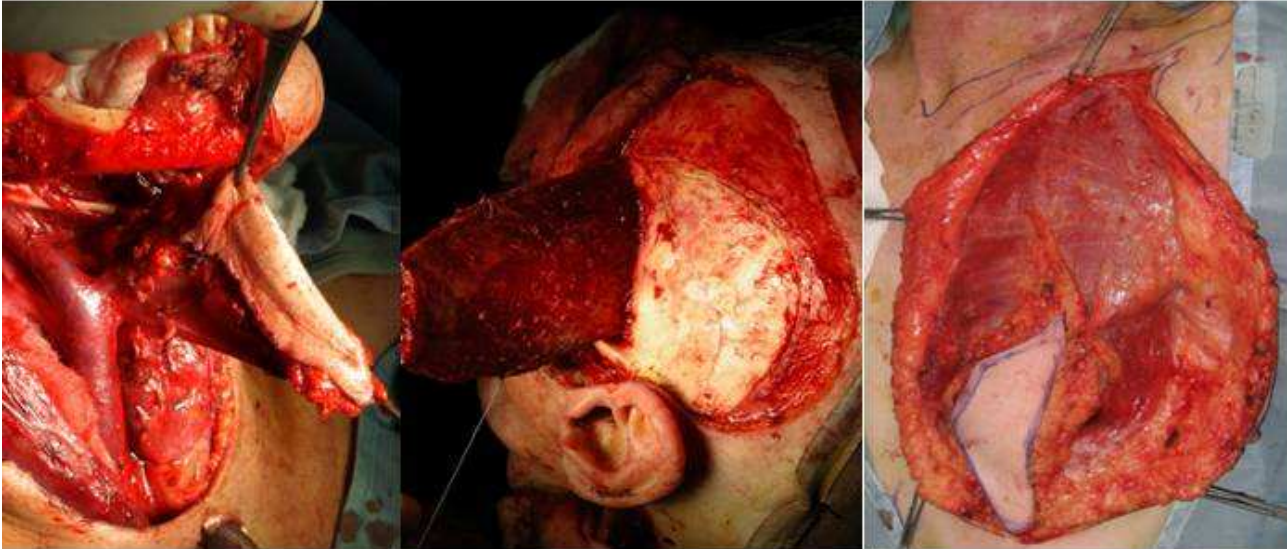


In current practice, surgeons frequently deal with elderly patients suffering from severe medical comorbidities and/or pre-treated patients with recurrent disease or second primary malignancies. There are no agreed-upon universally validated contraindications for microvascular reconstruction in head and neck surgery; the trend in recently published reports is to extend indications for free flaps even in generally compromised patients and in unfavourable anatomic situations such as vessel depleted neck and previous chemo-radiation^{2,3}. This despite the risk that general comorbidities, especially diabetes mellitus, pose to the success of microvascular transfers⁴.

That not all patients are ideal candidates for free flap reconstruction, and that not every defect strictly requires a free flap transfer to achieve good functional results, invites the evaluation of valid alternatives. Several reports indicate the reliability and good functional results of alternative

pedicled flaps such as the infrahyoid fascio-myocutaneous flap (IHF)^{5,6}, the temporalis myofascial flap (TMF)^{7,8} and the pectoralis major flap (PMF)^{9,10}.

Figure 2 *Infrahyoid fascio-myocutaneous flap, temporalis myofascial flap, pectoralis major flap*



All these flaps were extensively used in the past and tend to be overlooked in current practice even if they could represent a valid alternative in selected cases.

At our Academic Institution FRFF remains the first choice for soft tissue reconstruction of oral cavity and oropharyngeal defects. However, instead of performing free flap reconstructions in cases that are considered to be unsuitable or suboptimal for microvascular procedures, alternative pedicled flaps are considered. IHF represents our first alternative to FRFF in high risk patients with severe general comorbidities. TMF and PMF are used in patients with unfavourable anatomic conditions (vessel depleted neck or previous chemoradiation), or if contraindications to performing an infrahyoid flap are found (previous thyroid surgery or neck dissection, N3 neck metastasis, positive lymphnodes at level III-IV, previously irradiated neck)

In order to validate this approach, we critically reviewed our recent experience at our Clinic; we compared healing and functional results in oral cavity and oropharyngeal soft tissue reconstructions among 3 groups of patients: subjects in good general medical state who received FRFF reconstruction (group 1, G1), patients who received IHF (group 2, G2) and those who received TMF / PMF (group 3, G3).

MATERIALS AND METHODS

Data Collection

We reviewed the medical records of 86 consecutive patients who had free flap or pedicled flap reconstruction, performed by Alberto Deganello, at the Department of Otolaryngology / Head and Neck Surgery of the University of Florence, Italy, between July 2006 to May 2010.

Follow-up data were obtained in all patients using clinical chart notes. Disease was staged according to the 7th edition of the TNM classification established by the UICC/AJCC¹¹ using all the information available, including physical findings, imaging studies, and pathology reports.

The preoperative medical status of each patient was assessed by the anaesthesiologists using the American Society of Anesthesiologists (ASA) classification of physical status.

Follow-up data including status of the flap, complications and functional results were collected. Postoperative functional results were assessed by the physician at outpatient follow-up consultation; the type of diet was assessed in all cases. Options were numerically weighted from 1 to 4 as shown in Table 1.

Table 1. *Functional analysis*⁹

Score	Diet	Speech
1	regular diet without restrictions	always understandable
2	moist or soft diet	usually understandable, but with frequent repetition or face to face contact required
3	liquid diet	difficult to understand even with face to face contact
4	tube-dependent intake	never understandable, with written communication required

Patients

From the 88 consecutive head and neck reconstructions we identified 68 cases in which the defect of the oral cavity or oropharynx was in communication with neck spaces as result of transmandibular or pull-through approaches. The reconstruction was accomplished with FRFF in 16 patients, with IHF in 18, PMF in 16, fibula osteo-cutaneous flap in 5, rectus abdominis flap in 2, latissimus dorsi in 1 and with TMF in 10 patients.

This study focuses on soft tissue reconstructions, and therefore all reconstructions following segmental bony resections (mandibular resections / maxillectomies) were excluded, resulting in a study population of 54 patients. We compared results among 16 patients in good general conditions that received FRFF reconstruction, Group 1 (G1), 18 patients who had IHF reconstruction, and 20 patients that underwent TMF or PMF reconstruction (6 patients were not included because the PMF was used as alternative to fibula osteocutaneous flaps for reconstruction of lateral segmental mandibular defects).

G1 accounted for 12 male and 4 female patients; 9 patients received a FRFF to reconstruct a defect of the oral cavity while 7 patients had a reconstruction of the oropharynx. The mean age in G1 was 58.2 years (median 58, range 45-70 years) and all patients were classified ASA I-II. The mean dimensions of the skin paddle of the FRFF were 7.1cm x 6.3cm (mean surface area 44.7cm²). In all cases end-to-end arterial anastomoses were performed between the facial and radial arteries.

In 11 cases a single venous anastomosis was performed while in 5 cases a double venous drainage was provided. In all cases the main recipient vessel was the internal jugular vein. In 2 cases anastomoses were performed on the contralateral side of the primary tumor.

G2 accounted for 12 male and 6 female patients, 12 receiving IHF for oral cavity and 6 for oropharyngeal reconstruction. All flaps were harvested from the same neck side of the primary tumor during homolateral neck dissection; 10 patients had bilateral neck dissection. For flap harvesting technique we refer to our previous report⁵.

The mean age in G2 was 69.6 years (median 72, range 55-83 years), 3 patients were classified ASA II, the remaining ASA III. The mean dimensions of the skin paddle of the IHF were 6.5cm x 3.5cm (mean surface area 22.7cm²). Contraindications for FRFF reconstruction in G2 were: severe comorbidities (diffuse atherosclerosis with positive Allen's test, diabetes mellitus, heart failure) in 15 cases, and age exceeding 80 years with moderate comorbidities in 3 cases.

G3 accounted for 16 male and 4 female patients, 11 reconstructions of the oral cavity (7 PMF and 4 TMF) and 9 reconstructions of the oropharynx (3PMF and 6TMF). The mean age in G3 was 69.6

years (median 70, range 64-81 years); 3 patients were classified ASA I, 14 patients ASA II, 2 patients ASA III, 1 ASA IV. The skin paddle was harvested in 4 PMF with mean dimensions 5.3cm x 8.9cm (mean surface area 44cm²), while exclusive myofascial transposition was performed in all other cases.

The contraindications for FRFF and IHF in G3 were: age exceeding 80 years with severe comorbidities and contraindications for IHF reconstruction in 3 cases; post surgical vessel-depleted neck and previous radiation in 10 cases, and previous chemoradiation in 7 cases. Ten patients with vessel-depleted neck had no neck dissection, however even in these cases tumor resection created a communication between the oral cavity/oropharynx and neck spaces.

Among groups we recorded and compared flap viability, operative time, blood loss and blood transfusion, postoperative intensive care unit (ICU) recovery, postoperative complications, postoperative reinterventions, duration of hospitalization, hospital readmissions related to head and neck surgery within 6 months, oral intake restoration time, time of tracheotomy closure, diet and speech assessment.

Statistical Analysis

Statistical analysis was performed with an IBM computer using STATA (Stata Corporation, College Station, TX). Differences in mean values among groups were tested with ANOVA; for categorical variables Chi-Square Pearson test was used: probability values less than .05 were considered statistically significant.

RESULTS

Patient characteristics and results are displayed and summarized in Table 2.

The mean operative time in G1 was 9 hours (range 7h – 12h 40min), in G2 6 hours 40 minutes (range 5h 20min – 8h), and in G3 7 hours (range 5h 10min – 8h 30min).

Postoperative intensive care recovery was used in 4 patients in G1 with a mean stay of 3.7 days, in 4 G2 patients with a mean stay of 3 days and in 3 G3 patients with a mean stay of one day.

Flap Survival

No total flap necrosis was experienced in the series; successful separation between oral cavity/oropharyngeal contents and neck spaces was obtained in all patients.

In G1, one patient required postoperative revision of the venous anastomosis 8 hours after the end of surgery; intraluminal thrombus was found and removed at the end-to-side confluence between cephalic vein and the preserved caudal stump of the internal jugular vein. The flap reconstructed the lateral oropharyngeal wall and half soft palate. After microvascular revision the flap slowly developed marginal necrosis on its upper distal third. Further reconstruction of the soft palate using the remaining uvula under local anaesthesia was required to prevent open rhinolalia and nasal regurgitation.

In G2, 1 patient developed a venous congestion revealed by the colour of the skin paddle. Superficial cuts were made on the flap and heparin solution was injected twice a day; after one week the necrotic skin was removed revealing underlying healthy muscles. Complete re-epithelisation occurred within 3 weeks (Figure 1).

In G3, 3 patients developed a marginal necrosis in the distal portion of the myocutaneous PMF that was used to reconstruct a lateral oropharyngeal defect with extension to the mobile tongue and base of tongue; no treatment was required.

Another patient developed an oro-cutaneous fistula 30 days after hospital discharge during adjuvant radiotherapy. He received myofascial transposition of PMF after marginal mandibulectomy with resection of the floor of mouth and posterior third of the mobile tongue because of a pT4aN3

retromolar trigon carcinoma. The fistula was successfully closed under local anaesthesia with transposition of facial artery musculo-mucosal flap (FAMM)¹² without interrupting the radiation schedule. No other patients were readmitted within 6 months.

Complications

The overall rate of complications is 25.9% (14/54) including partial necrosis (5/54), fistulas (1/54) and postoperative pneumonia (8/54). The rate of complications that required surgical revision was 3.7% (2/54). Indications for surgical revision were: venous congestion and subsequent marginal necrosis in one G1 case and oro-cutaneous fistula in one G3 case. The remaining complications were successfully treated with conservative management.

Functional Results

All patients were discharged with complete restoration of oral intake (mean time 15 days, range 7-18) and tracheotomy closure (mean time 7 days, range 3-11). Mean discharge time after surgery was 23 days (range 12-39) with no differences between groups (23,2 days G1; 21,8 days G2; 26,5 days G3). No significant differences were found as regard to verbal intelligibility and diet score among groups. Nevertheless patients in G3 receiving TMF had minimal diet restrictions while all patients with PM flap reconstruction required soft or liquid diets.

Table 2. Patients Overview and statistical analysis.

	Groups			p*	Total (54)
	G1 (16)	G2 (18)	G3 (20)		
Age (yrs), mean (SD); range	58.2, (6.32); 45-70	69.6, (9.41); 55-83	69.6, (6.8); 64-81	p<0.01	64.7, (9.5); 45-83
Gender, n (%)					
male	12 (75)	12 (66)	16 (80)	p=0.88	40 (74)
Female	4 (25)	6 (34)	4 (20)		14 (26)
Tumor Site	9 OC 7 OP	12 OC 6 OP	11 OC 9 OP	p=0.61	32 OC 22 OP
Primary Tumor	12	15	3		30
Recurrent Tumor	2	2	7		11
Second Primary	2	1	10		13
pT					
1	-	-	4	p<0.01	4
2	7	5	5		17
3	8	9	8		25
4a	1	4	3		8
pN (10 G3 patients had no neck dissection)					
0	4	8	2	p=0.07	14
1	2	2	-		4
2a	1	-	-		1
2b	5	6	3		14
2c	4	2	2		8
3	-	-	3		3
Adjuvant Radiation, n (%)					
Yes	4 (25)	6 (33)	2 (10)	p=0.21	12 (22)
No	12 (75)	12 (67)	18 (90)		42 (78)
Adjuvant ChT-RT					
Yes	6 (37)	3 (17)	0	p=0.01	9 (16)
No	10 (63)	15 (83)	20	45 (84)	
Previous RT					
Yes	2 (12)	1 (5)	10 (50)	p=0.03	13 (24)
No	14 (88)	17 (95)	10 (50)		41 (76)
Previous ChT-RT					
Yes	0	0	7 (13)	p=0.20	7 (13)
No	0	0	13 (87)		48 (87)
Skin Paddle Surface (cm ²)					
mean (SD)	44.7 (15.5)	22.7 (4.5)	44 (16.9)	p<0.01	34.7 (15.9)
range	20-63	18-40	32-56		18-63
Operative time, (h), mean (SD); range	9.5 (1.6); 7-12.4	6.6 (0.8); 5.2-8	7.4 (0.9); 6.1-8.3	p=0.14	8 (1.8); 5.2-12.4
Blood loss (Hb g/dL), mean (SD); range	3.25 (1.4); 1.1-6.2	2.6 (1); 0.4-3.5	3.6 (2.6); 1.7-5.5	p=0.59	3.04 (1.4); 0.4-6.2
Patients blood-transfused, n (%)					
Yes	3 (19)	3 (17)	4 (20)	p=0.96	10 (19)
No	13 (81)	15 (83)	16 (80)		54 (81)
Tracheotomy closure, mean (days)	6 (4.2); 3-9	7.4 (2.7); 4-11	7 (2.1); 5-10	p=0.83	7.3 (2.8); 3-11
Oral intake restoration, mean (days)	14.8 (10); 8-40	11.5 (5.9); 6-25	12.6 (4.7); 9-18	p=0.63	13.2 (7.9); 6-40
Discharge, (days), mean (SD) range	23.2 (7.5); 16-39	21.8 (12); 12-61	26.5 (9.9); 16-38	p=0.63	23.2 (9.8); 12-61
Diet score, n, mean (SD); range	1.33 (0.4); 1-2	1.28 (0.4); 1-2	1.6 (0.7); 1-3	p=0.29	1.42 (0.6); 1-3
Speech score, mean, n	1 (0); 1-1	1.07 (0.2); 1-2	1.2 (0.4); 1-2	p=0.28	1.06 (0.2); 1-2

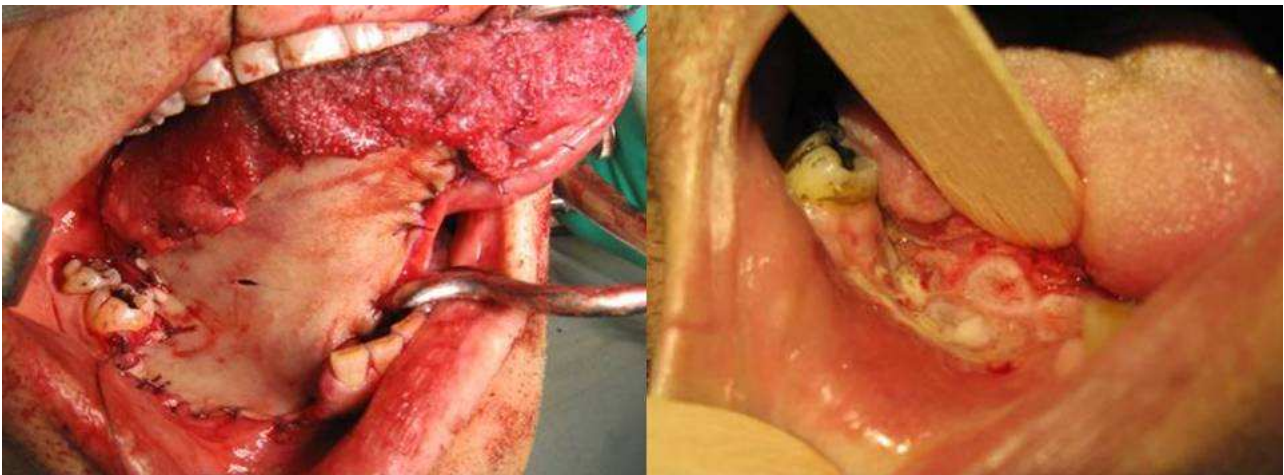
SD: Standard deviation; ChT: Chemotherapy; RT: Radiotherapy; Hb: Hemoglobin; OC: Oral Cavity; OP: Oropharynx;

* Differences in mean values among groups were tested with ANOVA, for categorical variables Chi-Square Pearson test was used.

DISCUSSION

Reconstruction of oral cavity and oropharyngeal defects requires a thoughtful approach in order to guarantee a safe healing process and to enhance residual functionality. In the present study, we analyzed reconstructions performed by the Author to avoid inter-operator differences and we focused on soft tissue reconstructions to test different options. We selected only defects in communication with neck spaces to represent a similar level of complexity in these reconstructions. In fact transoral resections are mostly performed for small tumors, where the reconstruction in these cases is less difficult, employing primary closure, local flaps or skin grafts only.

Figure 3 *Skin graft reconstruction after transoral resection.*



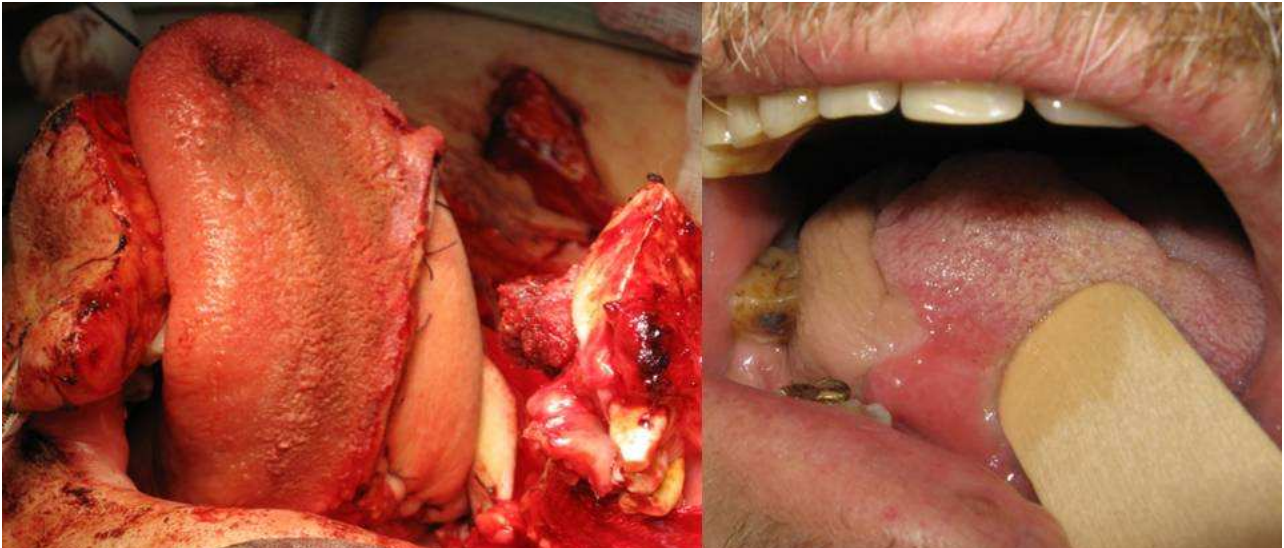As voluntary dynamic reconstruction is not achievable currently, optimal reconstructive outcome would be aimed at enhancing residual function and allowing good mobility of the preserved structures around the resected area. The replacement of dynamic structures with static ones has obvious limitations so that a thoughtful analysis of the anticipated defect and impairment is mandatory.

In cases of impaired function of the mobile tongue, the patients' ability to chew, propel food, maintain oral hygiene, and articulate are adversely affected. A decrease in function of the tongue base may lead to impaired deglutition and hence aspiration. Soft palate incontinence creates open rhinolalia and nasal regurgitation. Elasticity decrease of the buccal mucosa, of the floor of mouth or

of the lateral pharyngeal wall respectively lead to difficult mouth opening, tongue ankylosis and dysphagia. These impairments impact on the patient's diet, social interaction and quality of life.

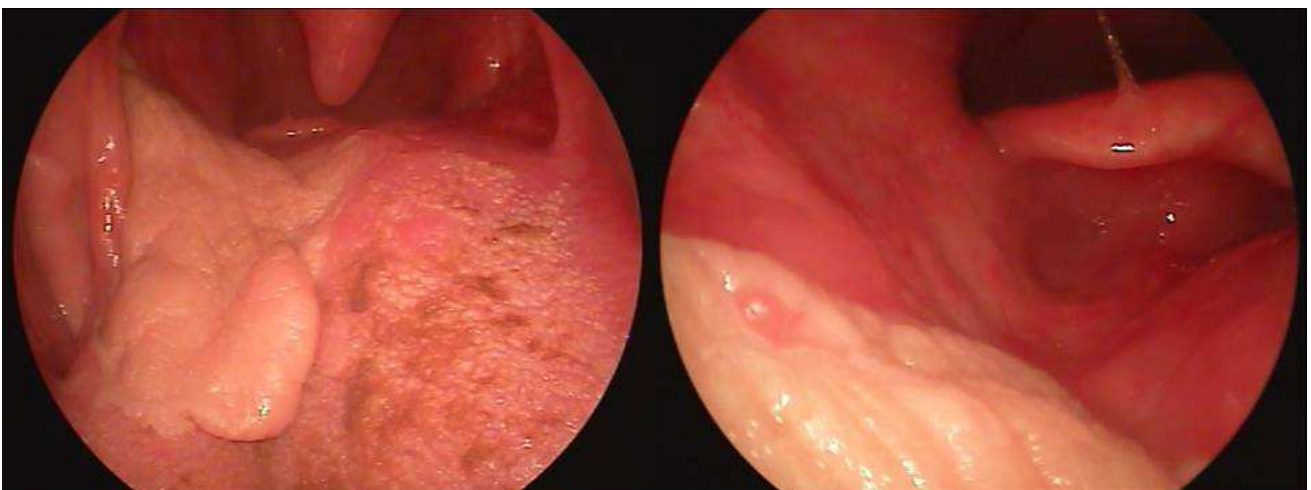
In our series FRFF appeared to be an excellent reconstructive method confirming all advantages that makes it the most popular and widespread microvascular flap in head and neck reconstruction.

Figure 4 *Free radial forearm flap reconstruction of the mobile tongue*



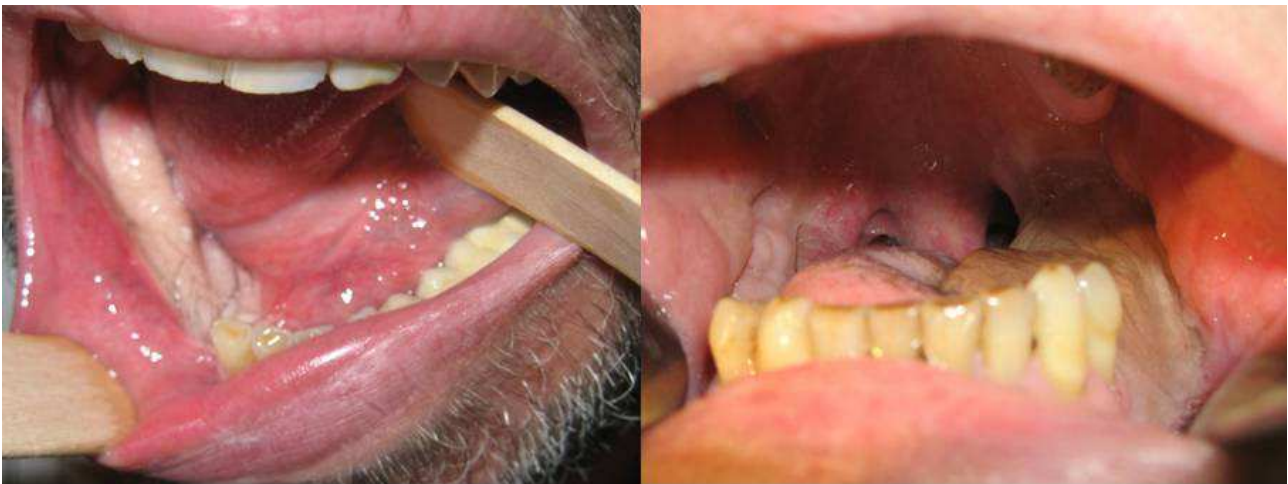In cases of complex defects involving more subsites FRFF, in our opinion, remains the surgical option of choice, providing excellent results. Offering a large amount of thin pliable skin that can be tailored, FRFF conforms well to the native contours of the recipient site so that defects encompassing the tonsillar region with extension to the soft palate and to the tongue base and/or oral cavity are well covered.

Figure 5 *Free radial forearm flap reconstruction of the mobile tongue and tongue base*



In our series the distal portion of this flap was double folded to reconstruct soft palate defects extending over the midline in 2 cases; it provided excellent lining for tongue resections with extension to the floor of mouth and alveolar ridge without interfering with residual tongue motility in 8 cases.

Figure 6 *Free radial forearm flap reconstruction of the mobile tongue, floor of mouth and alveolar ridge*

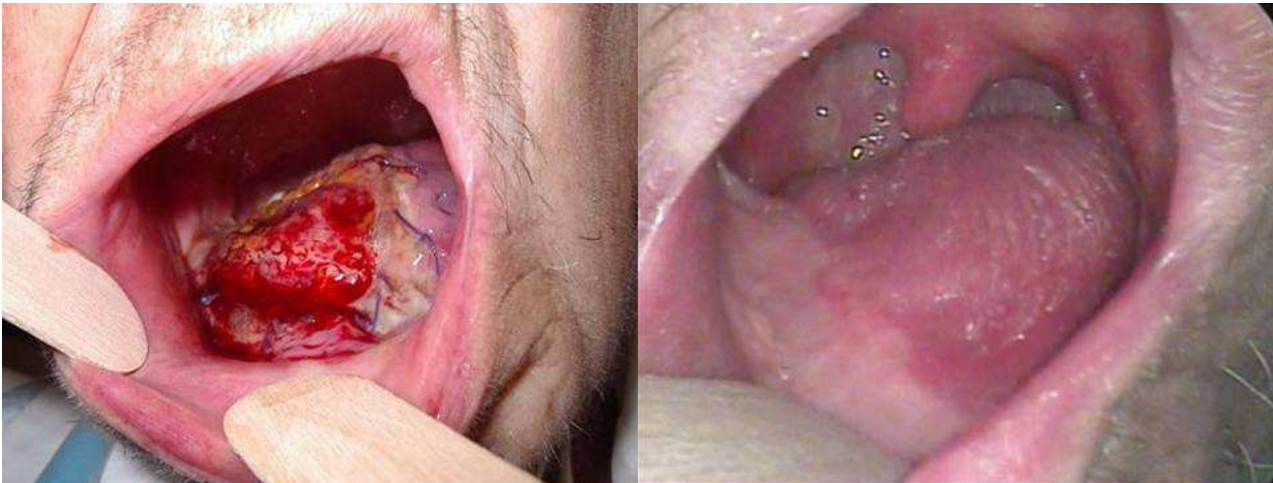

The long pedicle allowed anastomoses to be performed in the contralateral neck side in 2 cases. We experienced one case of venous congestion that was solved with microvascular revision. The problem was caused by a displacement of the caudal remaining stump of the internal jugular vein that had been superiorly fixed to prevent collapse and to facilitate venous drainage from the flap and from the middle thyroid vein. It is likely that, in this situation, extra-venous anastomosis between one comitant vein and the external jugular system might have overcome venous congestion. In a recent large study analyzing risk factors in free flap reconstruction, it was found that single venous anastomosis was more associated with flap compromise compared to double anastomoses, however the difference did not reach statistical significance⁴.

IHF represented an excellent alternative solution to FRFF in high-risk populations. Average age in G2 was 11 years higher than in G1, patients presented severe comorbidities with 83.3% (15/18) assessed as being ASA III. Despite this, all patients had a successful reconstruction with excellent functional results. In 1 elderly patient with severe diabetes mellitus, we experienced superficial skin

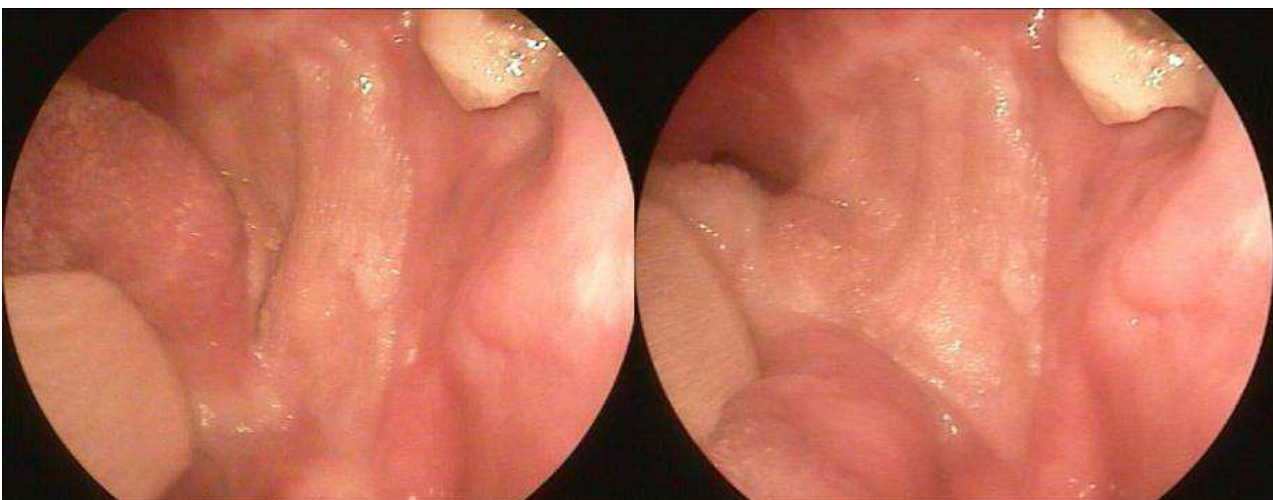necrosis but healthy muscles provided complete re-epithelisation without scar fixation of the residual tongue.

Figure 7 *Infracyoid flap reconstruction of the mobile tongue in high risk elderly and diabetic patient*



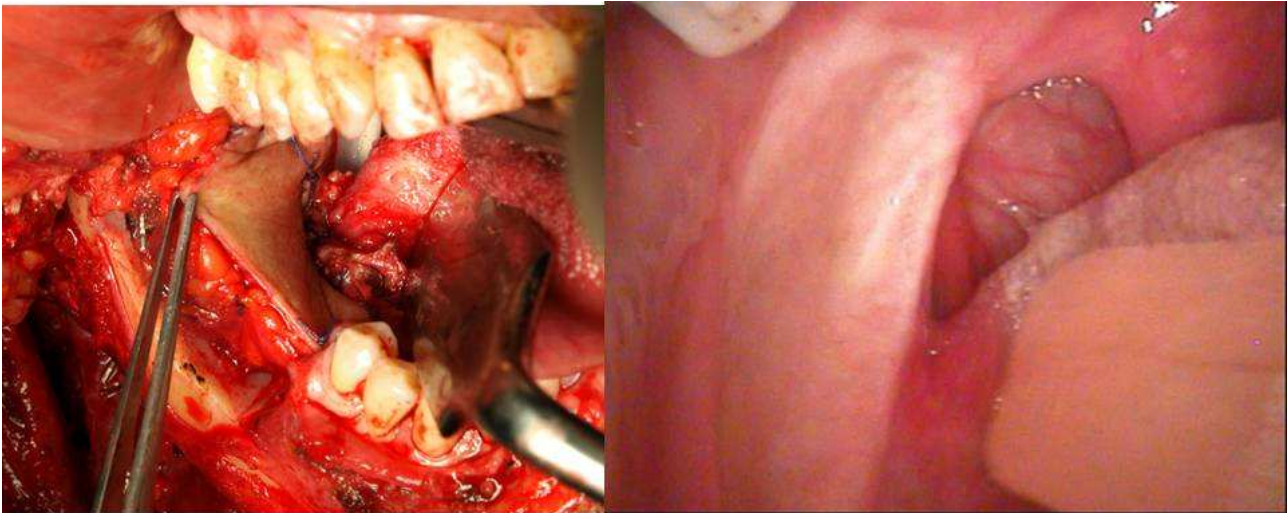
The majority of myocutaneous flaps for head and neck reconstruction (eg, pectoralis major, trapezius, latissimus dorsi) are quite bulky; conversely the IHF is thin and pliable. While the latter is not as thin and pliable as FRFF, it appears to be extremely suitable for floor of mouth or retromolar trigon reconstruction (especially in case of marginal mandibulectomy) preventing salivary fistulas in the neck and allowing good motility of the tongue.

Figure 8 *Infracyoid flap reconstruction of the mobile tongue and retromolar trigon*



For medium sized oropharyngeal defects with limited extension into the oral cavity, IHF is extremely useful; in our series IHF effectively reconstructed tonsillar region and soft palate defects in 3 cases.

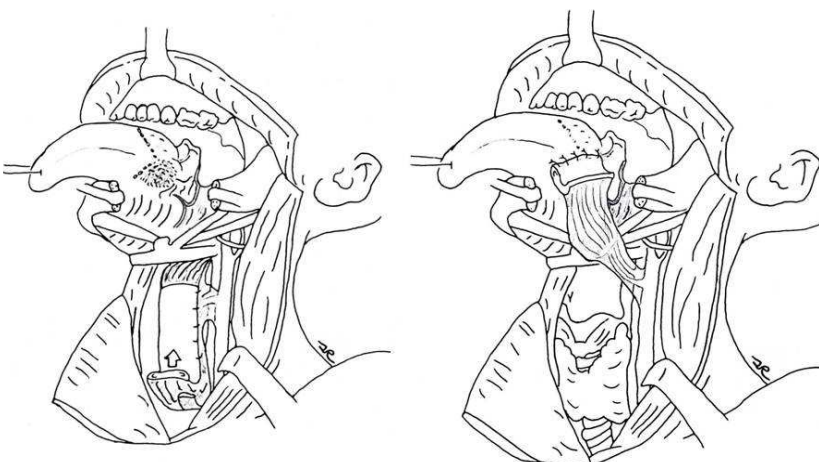Figure 9 *Infrahyoid flap reconstruction of the tonsillar region, soft palate and retromolar trigon*



In cases of tongue reconstruction our practice is to always preserve the motor innervations of the infrahyoid muscles (provided by the ansa cervicalis) to prevent subsequent atrophy.

Furthermore we are pleased to highlight a new personal modification of the surgical technique for base of tongue reconstruction that was used in this series.

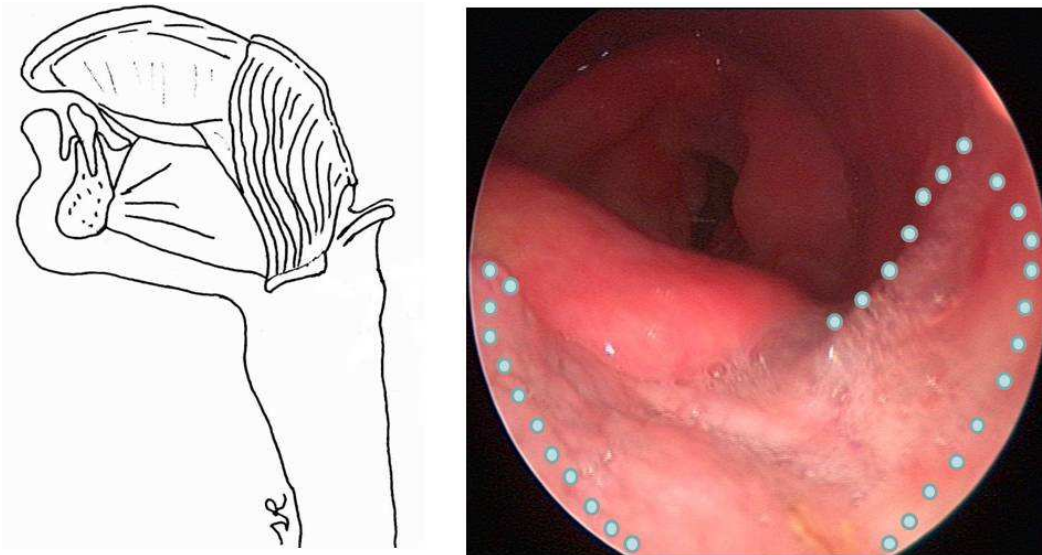
Figure 10 *Infrahyoid flap reconstruction of the base of tongue preserving hyoid muscular insertions*



We noted that, in cases of tongue base reconstruction, the transposition of the flap without detaching it from the hyoid bone (that acts as rotational pivot), improves swallowing efficacy.

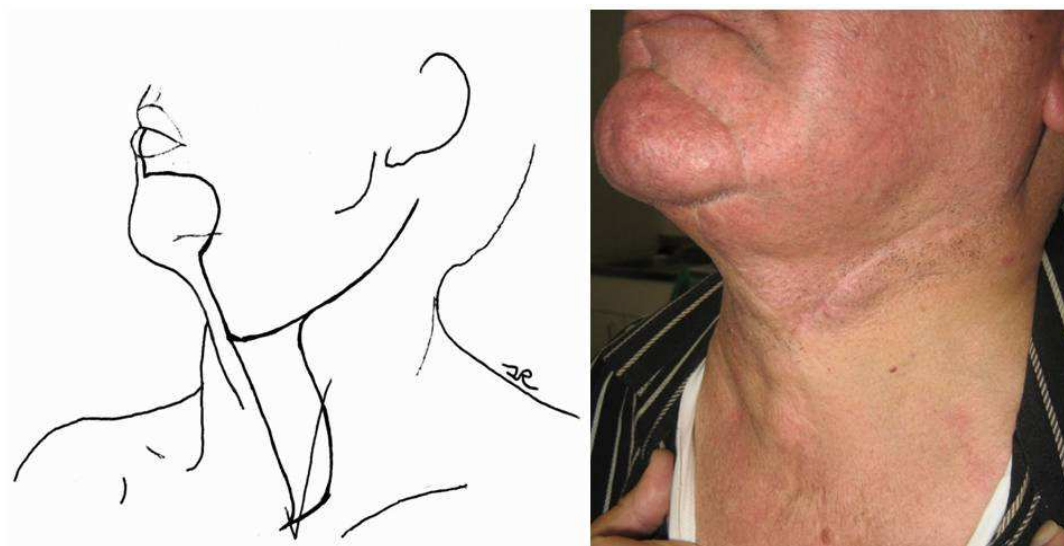
In fact, during deglutition, the hyoid bone elevates and squeezes the flap backwards, so helping with bolus propulsion (as showed by dynamic fibroscopic investigations). For defects limited to the tongue base, IHF is perfectly suited to the resected area having the desired thickness. For all above-mentioned reasons IHF became our preferred method for base of tongue reconstructions.

Figure 11 *Infracyoid flap reconstruction of the base of tongue*



IHF reconstruction proved to be quick: the average operative time in G2 was 2 hours and 20 minutes less than it was in G1; furthermore in G2 only one surgical team was needed. The flap was harvested after neck dissection without interfering with oncologic radicality and all donor sites were primary closed with good results.

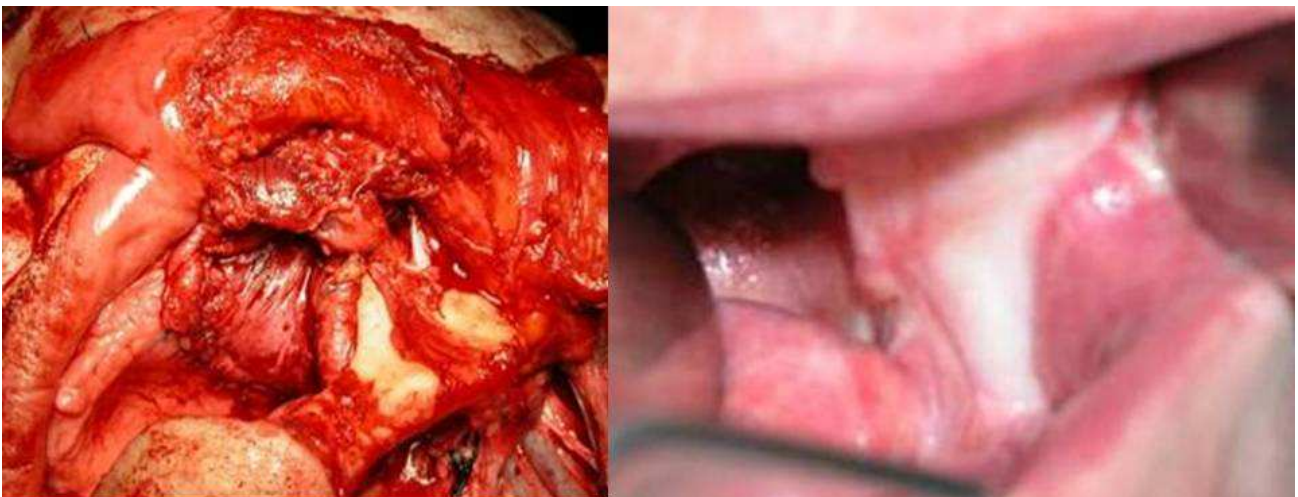
Figure 12 *Surgical incision for infracyoid flap and donor site result after direct closure*



Mean reconstructed surface area was 22.7cm², making this flap particularly suitable for medium sized defects; nevertheless, for larger defects, skin paddles measuring 9x4.5cm (40,5cm²) and 7.5x4cm (30cm²) have been easily transposed in this series. Disadvantages of IHF mainly coincide with its contraindications: previous thyroid surgery or neck dissection, N3 neck metastasis, and positive lymphnodes at level III-IV. This flap is also better not harvested in previously irradiated necks.

Patients with TMF reconstruction had excellent results. TMF was used to reconstruct 4 buccal mucosa defects of which 1 had extension to the superior retromolar trigon, 2 had lateral oropharyngeal wall defects and 4 had total soft palate resections for recurrences after radiotherapy or chemoradiation. Even if the use of this flap has been described for a wide range of head and neck reconstructions of the oral cavity and oropharynx, in our opinion it should be better confined to reconstruct defects lying above an imaginary line passing through the angle of the mandible and labial commissure.

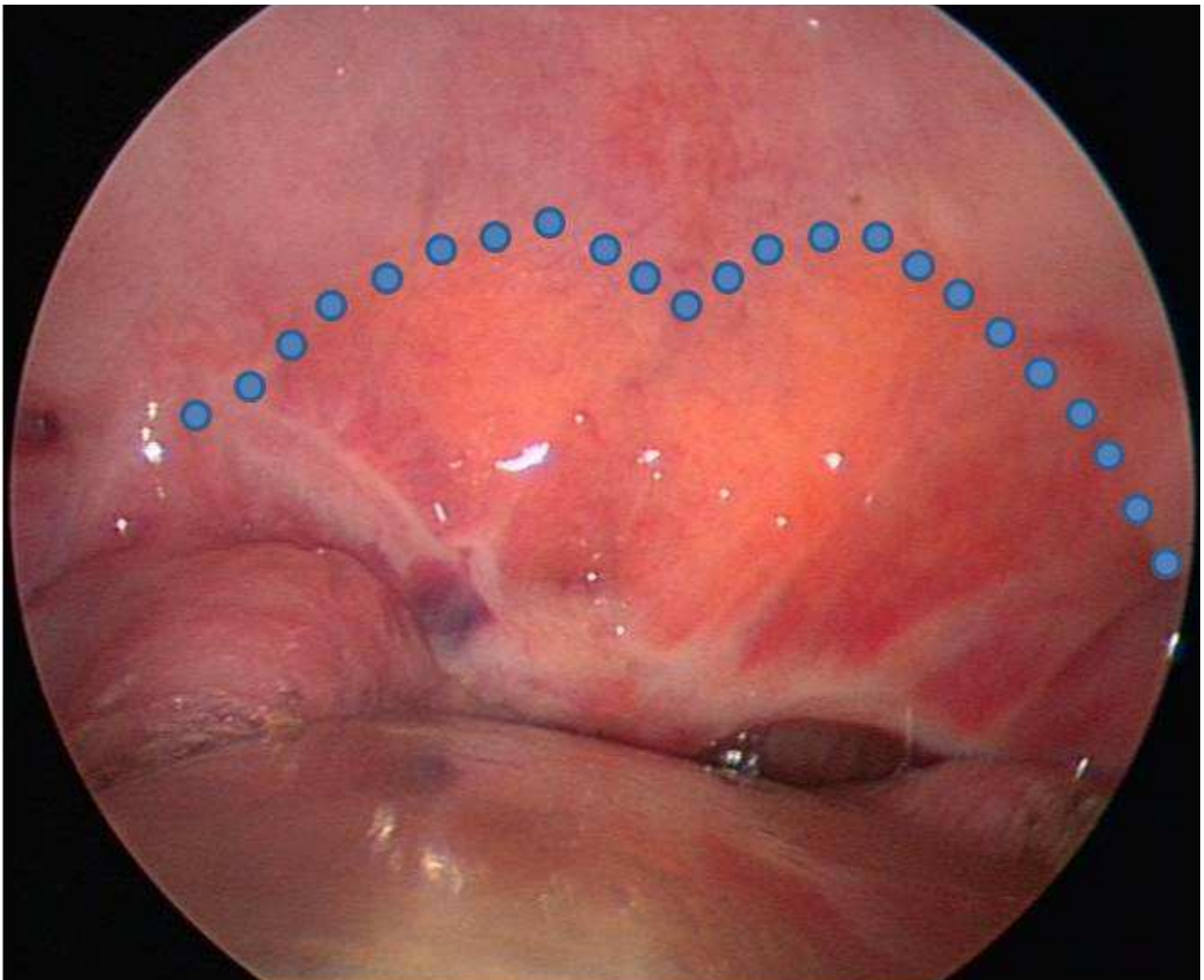
Figure 13 *Temporalis myofascial flap reconstruction of superior retromolar trigon after previous Chemoradiation*



Soft palate carcinomas are mainly managed with non surgical treatments since they are radiosensitive and also because total resection of the soft palate represents a reconstructive challenge. In case of radiation failure a double folded FRFF or the transposition of TMF can both effectively reconstruct this type of defect. In our series we had 4 cases of total soft palate

reconstructions after radiation failure, and all patients received a TMF with excellent results. We believe that the risk of dehiscence is significant for a fascio-cutaneous flap hanging from irradiated tissue, conversely a myofascial flap rotated down from an upper position is less likely to detach because it maintains some upper muscular insertions that provide for weight support.

Figure 14 *Temporalis myofascial flap reconstruction of total soft palate resection after previous Chemoradiation. Dotted line indicates the posterior limit of the hard palate.*

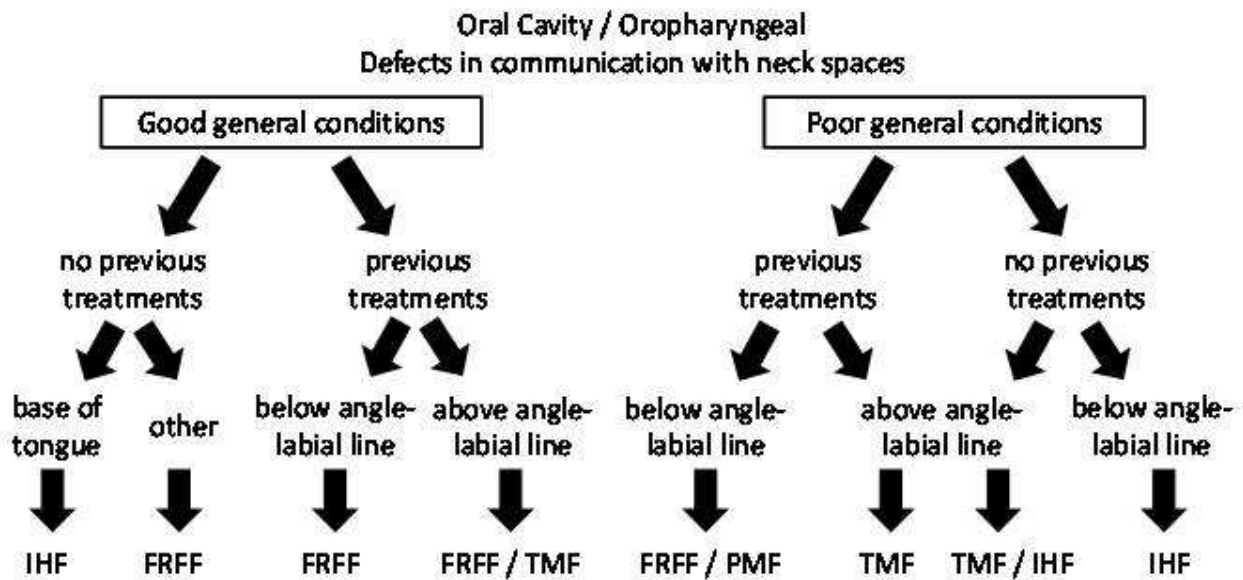


Our data showed that PMF reconstruction was not optimal as regard to deglutition, with all 10 patients requiring a soft or liquid diet. In case of transmandibular conservative resection, PMF reconstruction appears less than ideal because the mandible presses upon the flap favouring hypovascularization and necrosis of the distal portion, and because the thickness and bulkiness of

the flap hinders the motility of the preserved structures. Therefore, for most cases, we prefer myofascial transposition rather than myocutaneous one.

We have summarized our approach for oral cavity and oropharyngeal soft tissue reconstruction in

Table 3.



CONCLUSION

In our recent experience, FRFF still remains first choice flap for many oral cavity and oropharyngeal reconstructions. IHF in high-risk cases represents a valid alternative with excellent functional results, furthermore we introduced a novel technical innovation for tongue base reconstruction using the IHF so that it has become our preferred method for this specific area and we are now using it as first choice rather than FRFF.

For unfavourable anatomic conditions such as vessel depleted neck and/or previous chemoradiation, TMF provides an excellent reconstruction option with good functional results for defects lying above an imaginary line passing through the angle of the mandible and the labial commissure.

PMF is still a safe method, providing adequate reconstruction in terms of wound healing. Nevertheless, where conservative transmandibular approaches are employed, its bulkiness produces less than ideal functional outcomes. Therefore, in unfavourable patients presenting also contraindications for IHF and for TMF, a reconsideration of various microvascular options should be made before proposing PMF reconstruction. In this light PMF reconstruction could be reserved for cases of free flap failure.

ACKNOWLEDGMENT

Thanks to my wife Chiara for always supporting me.

Thanks to Sabino Russo, MD, for surgical illustrations.

Thanks to Prof. Enrico de'Campora for his fruitful and inspiring cooperation.

REFERENCES

1. Suh JD, Sercarz JA, Abemayor E, Calcaterra TC, Rawnsley JD, Alam D, Blackwell KE. Analysis of outcome and complications in 400 cases of microvascular head and neck reconstruction. *Arch Otolaryngol Head Neck Surg.* 2004 Aug;130(8):962-6.
2. Jacobson AS, Eloy JA, Park E, Roman B, Genden EM. Vessel-depleted neck: techniques for achieving microvascular reconstruction. *Head Neck* 2008;30:201-7.
3. Hanasono MM, Barnea Y, Skoracki RJ. Microvascular surgery in the previously operated and irradiated neck. *Microsurgery* 2009;29:1-7.
4. Joo YH, Sun DI, Park JO, Cho KJ, Kim MS. Risk factors of free flap compromise in 247 cases of microvascular head and neck reconstruction: a single surgeon's experience. *Eur Arch Otorhinolaryngol* 2010;12. [Epub ahead of print]
5. Deganello A, Manciocco V, Dolivet G, Leemans CR, Spriano G. Infrahyoid fascio-myo-cutaneous flap as an alternative to free radial forearm flap in head and neck reconstruction. *Head Neck.* 2007 Mar;29:285-91.
6. Dolivet G, Gangloff P, Sarini J, Ton Van J, Garron X, Guillemin F, Lefebvre JL. Modification of the infra hyoid musculo-cutaneous flap. *Eur J Surg Oncol* 2005;31:294-8.
7. Abu-El Naaj I, Leiser Y, Liberman R, Peled M. The use of the temporalis myofascial flap in oral cancer patients. *J Oral Maxillofac Surg* 2010;68:578-83.
8. Abubaker AO, Abouzgia MB. The temporalis muscle flap in reconstruction of intraoral defects: an appraisal of the technique. *Oral Surg Oral Med Oral Pathol Oral Radiol Endod* 2002;94:24-30.
9. O'Neill JP, Shine N, Eadie PA, Beausang E, Timon C. Free tissue transfer versus pedicled flap reconstruction of head and neck malignancy defects. *Ir J Med Sci* 2010;12. [Epub ahead of print]

10. Mallet Y, El Bedoui S, Penel N, Ton Van J, Fournier C, Lefebvre JL. The free vascularized flap and the pectoralis major pedicled flap options: comparative results of reconstruction of the tongue. *Oral Oncol* 2009;45:1028-31
11. Sobin LH, Gospodarowicz M, Wittekind Ch, editors. *TNM classification of malignant tumors*, 7th ed. International Union Against Cancer; New York: Wiley-Liss; 2009.
12. Ayad T, Kolb F, De Monés E, Mamelle G, Temam S. Reconstruction of floor of mouth defects by the facial artery musculo-mucosal flap following cancer ablation. *Head Neck*. 2008;30:437-45.